

## Pediatric Two-Lumen Hemodialysis Catheterization Product

### Safety and Efficacy Considerations:

Do not use if package has been previously opened or damaged.

**Warning: Read all package insert warnings, precautions, and instructions prior to use. Failure to do so may result in severe patient injury or death.**

Do not alter the catheter, spring-wire guide, or any other kit/set component during insertion, use, or removal.

Procedure must be performed by trained personnel well versed in anatomical landmarks, safe technique, and potential complications.

### Indications for Use:

The dual-lumen hemodialysis catheter permits venous access to the central circulation system for rapid fluid administration, temporary or acute hemodialysis and apheresis. It may be inserted into the jugular, subclavian, or femoral veins of children, adolescents and small adults.

### Contraindications:

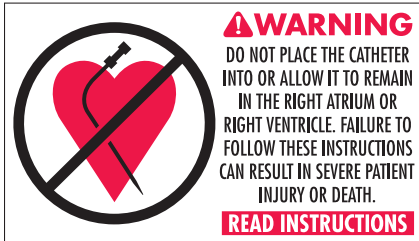The dual-lumen hemodialysis catheter is not designed for long-term hemodialysis or for use in patients with thrombosed vessels.

### Warnings and Precautions:\*

1. **Warning: Sterile, Single use: Do not reuse, reprocess or resterilize. Reuse of device creates a potential risk of serious injury and/or infection which may lead to death.**
2. **Warning: Use of subclavian vein insertion site may be associated with subclavian stenosis.**<sup>24,25,26,27</sup>
3. **Warning: Do not place the catheter into or allow it to remain in the right atrium or right ventricle. Central vein catheters should be positioned so that the distal tip of the catheter is in the lower 1/2 to 1/3 of the superior vena cava (SVC) above the junction of the SVC and the right atrium and lies parallel to the vessel wall. For femoral vein approach the catheter should be advanced into the vessel so that the catheter tip lies parallel to the vessel wall and does not enter the right atrium.**

Due to the variety of pediatric catheter lengths available, patient size must be carefully considered relative to actual length of catheter introduced.

4. **Warning: Practitioners must be aware of complications associated with central vein catheters including cardiac tamponade secondary to vessel wall, atrial or ventricular perforation, pleural and mediastinal injuries, air embolism, catheter embolism, thoracic duct laceration, bacteremia, septicemia, thrombosis, inadvertent arterial puncture, nerve damage, hematoma, hemorrhage, dysrhythmias, brachial plexus injury, cardiac arrhythmia, exsanguination, hemothorax, luminal thrombosis, pneumothorax, subcutaneous hematoma, and retroperitoneal bleed.**
5. **Warning: Do not apply excessive force in removing guide wire or catheters. If withdrawal cannot be easily accomplished, a chest x-ray should be obtained and further consultation requested.**
6. **Warning: The practitioner must be aware of potential air embolism/hemorrhage associated with catheters. Do not leave open needles or catheters in central venous puncture sites. To lessen the risk of disconnects, only securely tightened Luer-Lock connections should be used with this device. It is recommended that the extension lines be kept clamped at all times when not in use because of the catheter's large lumens. Follow hospital protocol to**



### Cardiac Tamponade:

It has been documented by many authors that placement of indwelling catheters in the right atrium is a dangerous practice<sup>1,2,3,5,7,14,16</sup> that may lead to cardiac perforation and tamponade.<sup>1,2,3,5,14,16</sup> Although cardiac tamponade secondary to pericardial effusion is uncommon, there is a high mortality rate associated with it.<sup>18</sup> Practitioners placing central venous catheters must be aware of this potentially fatal complication before advancing the catheter too far relative to patient size.

No particular route or catheter type is exempt from this potentially fatal complication.<sup>16</sup> The actual position of the tip of the indwelling catheter should be confirmed by x-ray after insertion.<sup>1,2,5,14,16,19</sup> Central venous catheters should be placed in the superior vena cava<sup>12,3,5,7,14,21</sup> above its junction with the right atrium and parallel to the vessel wall<sup>9,21</sup> and its distal tip positioned at a level above either the azygos vein or the carina of the trachea, whichever is better visualized.

Central venous catheters should not be placed in the right atrium unless specifically required for special relatively short term procedures such as aspiration of air emboli during neurosurgery. Such procedures are, nevertheless, risk prone and should be closely monitored and controlled.

guard against air embolism/hemorrhage for all catheter maintenance.

7. **Warning:** Passage of the guide wire into the right heart can cause dysrhythmias, right bundle branch block,<sup>8</sup> and vessel wall, atrial or ventricular perforation.
8. **Warning:** Practitioners must be aware of the potential for entrapment of guide wire by any implanted device to the circulatory system (ie. vena cava filters, stents). Review patient's history before catheterization procedure to assess for possible implants. Care should be taken regarding the length of spring wire guide inserted. It is recommended that if patient has a circulatory system implant, catheter procedure should be done under direct visualization to minimize the risk of guide wire entrapment.
9. **Warning:** Due to the risk of exposure to HIV (Human Immunodeficiency Virus) or other blood borne pathogens, health care workers should routinely use universal blood and body-fluid precautions in the care of all patients.
10. **Precaution:** Do not clamp the body of the catheter. Clamp only the extension lines and use only the clamps provided. Never use serrated forceps to clamp the extension lines.
11. **Precaution:** Indwelling catheters should be routinely inspected for desired flow rate, security of dressing, correct catheter positioning and for secure Luer-Lock connection. Use centimeter markings to identify if the catheter position has changed.
12. **Precaution:** Only x-ray examination of the catheter placement can ensure that the catheter tip has not entered the heart or no longer lies parallel to the vessel wall. If catheter position has changed, immediately perform chest x-ray examination to confirm catheter tip position.
13. **Precaution:** For blood sampling, temporarily shut off remaining port(s) through which solutions are being infused.
14. **Precaution:** Alcohol and acetone can weaken the structure of polyurethane materials. Check ingredients of prep sprays and swabs for acetone and alcohol content.  
**Acetone:** Do not use acetone on catheter surface. Acetone may be applied to skin but must be allowed to dry completely prior to applying dressing.  
**Alcohol:** Do not use alcohol to soak catheter surface or to restore catheter patency. Care should be taken when instilling drugs containing high concentration of alcohol. Always allow alcohol to dry completely prior to applying dressing.
15. **Precaution:** Some disinfectants used at the catheter insertion site contain solvents, which can attack the catheter material. Assure insertion site is dry before dressing.
16. **Precaution:** Use of a syringe smaller than 10 mL to irrigate or declot an occluded catheter may cause intraluminal leakage or catheter rupture.<sup>6</sup>  
Carefully read all warnings and precautions throughout procedure instructions.

Kits/Sets may not contain all accessory components detailed in these instructions for use. Become familiar with instructions for individual component(s) before beginning the procedure.

## A Suggested Procedure:

### Use sterile technique.

1. **Precaution:** Place patient in slight Trendelenburg position as tolerated to reduce the risk of air embolism. If femoral approach is used, place patient in supine position.
2. Measure the patient's external anatomy to estimate the length of catheter required to place the distal tip in the SVC.
3. Prep and drape puncture site as required.
4. Perform skin wheal with desired needle. In kits where provided, a SharpsAway<sup>®</sup> disposal cup is used for the disposal of needles. Push needles into foam after use. Discard entire cup at completion of procedure. **Precaution: Do not reuse needles after they have been placed into the disposal cup. Particulate matter may adhere to needle tip.**
5. Prepare the catheter for insertion by flushing each lumen and clamping or attaching the injection caps to the appropriate extension lines. Leave the distal extension line uncapped for guide wire passage. **Warning: Do not cut the catheter to alter length.**
6. Insert introducer needle with attached Arrow<sup>®</sup> Raulerson Syringe into vein and aspirate. (Vessel may be pre-located with locator needle and syringe appropriate to size of patient.) Remove locator needle.
7. **Precaution: The preferred insertion site for central venous catheters is the right internal jugular vein. Other options include the right external jugular vein, left internal and external jugular vein. Subclavian access should be used only when no other upper-extremity or chest-wall options are available.**<sup>28</sup>

### Alternate Technique:

Catheter/needle may be used in the standard manner as alternative to introducer needle. If catheter/needle is used, Arrow Raulerson Syringe will function as a standard syringe, but will not pass spring-wire guide. If no free flow of venous blood is observed after needle is removed, attach syringe to the catheter and aspirate until good venous blood flow is established. **Precaution: The color of the blood aspirated is not always a reliable indicator of venous access.**<sup>10</sup> Do not reinsert needle into introducer catheter.

8. Because of the potential for inadvertent arterial placement, one of the following techniques should be utilized to verify venous access. Insert the fluid primed blunt tip transduction probe into the rear of the plunger and through the valves of the Arrow Raulerson Syringe. Observe for central venous placement via a wave form obtained by a calibrated pressure transducer. Remove transduction probe (refer to Fig. 1).

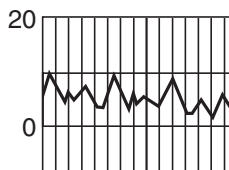


Fig. 1

#### Alternate Technique:

If hemodynamic monitoring equipment is not available to permit transducing a central venous wave form, check for pulsatile flow by either using the transduction probe to open the syringe valving system or by disconnecting the syringe from the needle. Pulsatile flow is usually an indicator of inadvertent arterial puncture.

- Using the two-piece Arrow Advancer, advance spring-wire guide through syringe into vein. **Warning: Aspiration with spring-wire guide in place will cause introduction of air into syringe. Precaution: To minimize the risk of leakage of blood from syringe cap, do not reinfuse blood with spring-wire guide in place.**

#### Arrow Two-Piece Advancer Instructions (where provided):

- Using your thumb, straighten the “J” by retracting the spring-wire guide into the Advancer (refer to Figs. 2, 3).

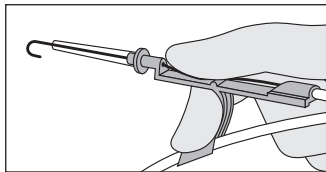


Fig. 2

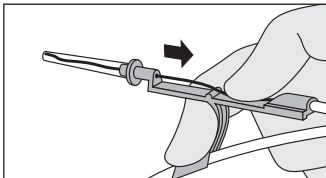


Fig. 3

When the tip is straightened, the spring-wire guide is ready for insertion. Where provided, centimeter marks on guide wire are referenced from “J” end. One band indicates 10 cm, two bands 20 cm, and three bands 30 cm.

#### Introducing the Spring-Wire Guide:

- Place the tip of the Advancer – with “J” retracted – into the hole in the rear of the Arrow Raulerson Syringe plunger (refer to Fig. 4).

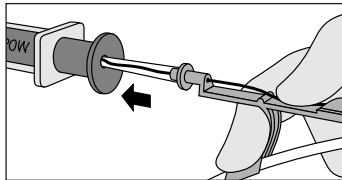


Fig. 4

- Advance spring-wire guide into the syringe approximately 10 cm until it passes through the syringe valves (refer to Fig. 5).

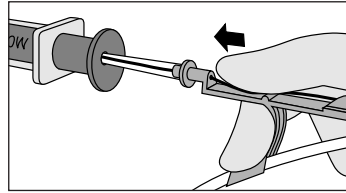


Fig. 5

- Raise your thumb and pull the Advancer approximately 4 cm away from the syringe (refer to Fig. 6). Lower thumb onto the Advancer and while maintaining a firm grip on the spring-wire guide, push the assembly into the syringe barrel to further advance the spring-wire guide.

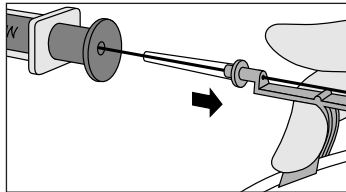


Fig. 6

#### Alternate Technique:

If a simple straightening tube is preferred, the straightening tube portion of the Advancer can be disconnected from the unit and used separately.

Separate the Advancer tip or straightening tube from the blue Advancer unit. If the “J” tip portion of the spring-wire guide is used, prepare for insertion by sliding the plastic tube over the “J” to straighten.

- Advance spring-wire guide to depth appropriate to size of patient. Advancement of “J” tip may require a gentle rotating motion. **Warning: Do not cut spring-wire guide to alter length. Do not withdraw spring-wire guide against needle bevel to minimize the risk of possible severing or damaging of spring-wire guide.**
- Hold spring-wire guide in place and remove introducer needle and Arrow Raulerson Syringe (or catheter). **Precaution: Maintain firm grip on spring-wire guide at all times.** Where provided, use centimeter markings on spring-wire guide to adjust indwelling length according to desired depth of indwelling catheter placement.
- Enlarge cutaneous puncture site with cutting edge of scalpel positioned away from the spring-wire guide. **Precaution: Do not cut guide wire.** Use vessel dilator to enlarge site as required. **Warning: Do not leave vessel dilator in place as an indwelling catheter to minimize the risk of possible vessel wall perforation.**
- Thread tip of two-lumen catheter over spring-wire guide. Sufficient guide wire length must remain exposed at hub end of catheter to maintain a firm grip on guide wire. Grasping near skin, advance catheter into vein with slight twisting motion.
- Using centimeter marks on catheter as positioning reference points, advance catheter to final indwelling position. All centimeter marks are referenced from the catheter tip. Marking symbology is as follows: (1) numerical: 5, 15, 25, etc.; (2) bands: each band denotes 10 cm intervals, with one

band indicating 10 cm, two bands indicating 20 cm, etc.; (3) each dot denotes a 1 cm interval. When using a subclavian approach, the catheter can be oriented with the outflow (arterial) sideholes toward the center of the vessel to reduce the possibility of contact between the outflow sideholes and the vessel wall.

15. Hold catheter at desired depth and remove spring-wire guide. The Arrow catheter included in this product has been designed to freely pass over the spring-wire guide. If resistance is encountered when attempting to remove the spring-wire guide after catheter placement, the spring-wire may be kinked about the tip of the catheter within the vessel (refer to Fig. 7).

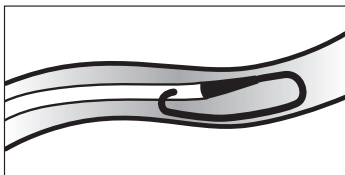


Fig. 7

In this circumstance, pulling back on the spring-wire guide may result in undue force being applied resulting in spring-wire guide breakage. If resistance is encountered, withdraw the catheter relative to the spring-wire guide about 2-3 cm and attempt to remove the spring-wire guide. If resistance is again encountered, remove the spring-wire guide and catheter simultaneously. **Warning: Although the incidence of spring-wire guide failure is extremely low, practitioner should be aware of the potential for breakage if undue force is applied to the wire.**

16. Verify that the entire spring-wire guide is intact upon removal.
17. Check lumen placement by attaching a syringe to each extension line and aspirate until free flow of venous blood is observed. Connect both extension lines to appropriate Luer-Lock line(s) as required. Unused port(s) may be “locked” through injection cap(s) using standard hospital protocol. Pinch clamps are provided on extension lines to occlude flow through each lumen during line and injection cap changes. **Precaution: To minimize the risk of damage to extension lines from excessive pressure, each clamp must be opened prior to infusing through that lumen.**
18. Secure and dress catheter temporarily.
19. Verify catheter tip position by chest x-ray immediately after placement. **Precaution: X-ray exam must show the catheter located in the right side of the mediastinum in the SVC with the distal end of the catheter parallel to the vena cava wall and its distal tip positioned at a level above either the azygos vein or the carina of the trachea, whichever is better visualized.** If catheter tip is malpositioned, reposition and re-verify.
20. Secure catheter to patient. Use triangular juncture hub as suture site. **Precaution: Do not suture directly to the outside diameter of the catheter to minimize the risk of cutting or damaging the catheter or impeding catheter flow.**
21. Dress puncture site per hospital protocol. **Precaution: Maintain the insertion site with regular meticulous redressing using aseptic technique.**

22. Record on the patient’s chart the indwelling catheter length as to centimeter markings on catheter where it enters the skin. Frequent visual reassessment should be made to ensure that the catheter has not moved.

#### Catheter Exchange Procedure:

1. Use sterile technique.
2. Proceed per hospital protocol. Cutting the catheter is not recommended due to the potential for catheter embolism.

#### Catheter Removal Procedure:

1. **Precaution: Place the patient in a supine position.**
2. Remove dressing. **Precaution: To minimize the risk of cutting the catheter do not use scissors to remove the dressing.**
3. **Warning: Exposure of the central vein to atmospheric pressure may result in entry of air into the central venous system.** Remove suture(s) from suture site. Be careful not to cut the catheter. Remove catheter slowly, pulling it parallel to the skin. As catheter exits the site, apply pressure with a dressing impermeable to air. Because the residual catheter track remains an air entry point until completely sealed, the occlusive dressing should remain in place for at least 24-72 hours dependent upon the amount of time the catheter was indwelling.<sup>11,15,17,20</sup>
4. Upon removal of the catheter, inspect it to make sure that the entire length has been withdrawn.
5. Document removal procedure.

#### Heparinization (Hemodialysis):

1. A variety of “locking” solution concentrations are utilized to maintain the patency of the catheter. The amount of heparin used depends on physician preference, hospital protocol, and patient condition.<sup>13</sup>
2. The volume of heparin solution should be equal to or slightly more than the volume of the lumen that is being “locked”.
3. **Warning: Prior to hemodialysis, the indwelling heparin must be aspirated from each lumen. After the heparin has been aspirated the lumens should be flushed with sterile normal saline solution.**

#### Poor Blood Flow:














1. If there is difficulty maintaining adequate blood flow during the hemodialysis treatment, the following measures can be tried: lower patient’s head, change patient’s position, apply external pressure to catheter exit site over sterile dressing, check for catheter kinks, loosen tight dressing, reverse blood flow only if other attempts fail.<sup>13</sup>
2. If the above measures fail and the flow problems are felt to be due to a clotted catheter, fibrinolytic agents can be used as prescribed.

#### References:

1. Bar-Joseph G, Galvis AG. Perforation of the heart by central venous catheters in infants: guidelines to diagnosis and management. *J Pediatr Surg.* June 1983;18:284-287.
2. Blitt CD, ed. *Monitoring in Anesthesia and Critical Care Medicine.* Central venous pressure monitoring. New York, NY: Churchill Livingstone; 1985:121-165.

3. Brandt RL, Foley WJ, Fink GH, Regan WJ. Mechanism of perforation of the heart with production of hydropericardium by a venous catheter and its prevention. *Am J Surg.* 1970;119:311-316.
  4. Carbone K, Gimenez LF, Rogers WH, Watson AJ. Hemothorax due to vena caval erosion by a subclavian dual-lumen dialysis catheter. *South Med J.* 1987;80:795-796.
  5. Collier PE, Ryan JJ, Diamond DL. Cardiac tamponade from central venous catheters – report of a case and review of the English literature. *Angiology.* September 1984;35:595-600.
  6. Conn C. The importance of syringe size when using implanted vascular access devices. *J Vasc Access Nurs.* Winter 1993;3:11-18.
  7. Curelaru J, Linder LE, Gustavsson B. Displacement of catheters inserted through internal jugular veins with neck flexion and extension. *Intens Care Med.* 1980;6:179-183.
  8. Eissa NT, Kvetan V. Guide wire as a cause of complete heart block in patients with preexisting left bundle branch block. *Anesthesiology.* 1990;73:772-774.
  9. Iberti TJ, Katz LB, Reiner MA, Brownie T, Kwun KB. Hydrothorax as a late complication of central venous indwelling catheters. *Surgery.* November 1983;84:842-846.
  10. Jobses DR, Schwartz AJ, Greenhow DE, Stephenson LW, Ellison N. Safer jugular vein cannulation: recognition of arterial punctures and preferential use of the external jugular route. *Anesthesiology.* 1983;59:353-355.
  11. Kashuk JL, Penn I. Air embolism after central venous catheterization. *Surg Gynecol Obstet.* September 1984;159:249-252.
  12. Kozeny GA, Bansal VK, Vertuno LL, Hano JE. Contralateral hemothorax secondary to chronic subclavian dialysis catheter. *Am J Nephrol.* 1984;4:312-314.
  13. Lancaster LE, ed. *ANNA Core Curriculum for Nephrology Nursing.* 2nd ed. Pitman, NJ: Anthony J. Jannetti, Inc.; 1990:270-271.
  14. Maschke SP, Rogove HJ. Cardiac tamponade associated with a multilumen central venous catheter. *Crit Care Med.* 1984;12:611-612.
  15. Paskin DL, Hoffman WS, Tuddenham WJ. A new complication of subclavian vein catheterization. *Ann Surg.* March 1974;179:266-268.
  16. Peters JL, ed. *A Manual of Central Venous Catheterization and Parenteral Nutrition.* Boston, MA: John Wright PSG; 1983:58-61, 155-157.
  17. Phifer TJ, Bridges M, Conrad SA. The residual central venous catheter track – an occult source of lethal air embolism: case report. *J Trauma.* 1991;31:1558-1560.
  18. Sheep RE, Guiney WB Jr. Fatal cardiac tamponade. *JAMA.* 1982;248:1632-1635.
  19. Sigurdsson J, Riba P, Sigurdsson S. The wandering central venous catheter. *Intensive Care Med.* 1985;11:263-264.
  20. Thielen JB, Nyquist J. Subclavian catheter removal. *J Intravenous Nurs.* March/April 1991;14:114-118.
  21. Tocino IM, Watanabe A. Impending catheter perforation of superior vena cava: radiographic recognition. *Am J Roentgenology.* March 1986;146:487-490.
  22. Vaziri ND, Maksy M, Lewis M, Martin D, Edwards K. Massive mediastinal hematoma caused by a double-lumen subclavian catheter. *Artif Organs.* 1984;8:223-226.
  23. Wanscher M, Frifelt JJ, Smith-Sivertsen C, et al. Thrombosis caused by polyurethane double-lumen subclavian superior vena cava catheter and hemodialysis. *Crit Care Med.* 1988;16:624-628.
  24. Acute Dialysis Catheters; Oliver MJ; Semin Dial. 2001 Nov-Dec; 14(6):432-5.
  25. Central Vein Stenosis: a Nephrologists' Perspective: Agarwal AK, Patel BM, Jaddad NJ; Semin Dial 2007 Jan-Feb 20:1:53-62.
  26. Post Catheterization vein Stenosis in Hemodialysis: Comparative Angiographic Study of 50 Subclavian and 50 Internal Jugular Accesses; Schillinger, F et al. Nephrol Dial Transplant 1991; 6:722-724.
  27. Thrombosis and Stenosis of Central Venous Access in Hemodialysis: Vanherweghem, JL. Nephrologie 1994;15 (2):117-121.
  28. National Kidney Foundation KDOQI Guidelines. Clinical Practice Guidelines and Clinical Practice Recommendations; Update 2006.
- Arrow International, Inc. recommends that the user be acquainted with the reference literature.
- \*If you have any questions or would like additional reference information, please contact Arrow International, Inc.

**Rx only.**

Symbol Glossary								
								
Caution	Consult instructions for use	Do not reuse	Do not resterilize	Sterilized by ethylene oxide	Keep away from sunlight	Keep dry	Do not use if package is damaged	Not made with natural rubber latex
								
Catalogue number	Lot number	Use by	Manufacturer					

K-11802-101A (6/15)

# ARROW<sup>®</sup>

INTERNATIONAL

2400 Bernville Road  
Reading, PA 19605 USA  
1-800-523-8446 | 1-610-378-0131