

ARROW

Multiple-Lumen Central Venous Catheterization Product with Arrow Raulerson Syringe

Safety and Efficacy Considerations:

The product is designed for single use only. Do not resterilize or reuse. Do not alter the catheter, spring-wire guide or any other kit/set component during insertion, use, or removal.

Central venous catheterization must be performed by trained personnel well versed in anatomical landmarks, safe technique and potential complications.

Warning: Do not place the catheter into or allow it to remain in the right atrium or right ventricle. Failure to follow these instructions can result in severe patient injury or death. Read instructions (refer to Fig. 1).

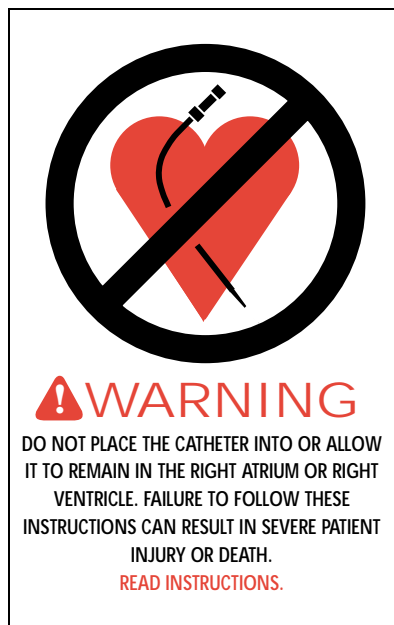

Fig. 1

Cardiac Tamponade: It has been documented by many authors that placement of indwelling catheters in the right atrium is a dangerous practice^{1,2,3,5,7,13,15} that may lead to cardiac perforation and tamponade^{1,2,3,5,13,15}. Although cardiac tamponade secondary to pericardial effusion is uncommon, there is a high mortality rate associated with it¹⁷. Practitioners placing central venous catheters must be aware of this potentially fatal complication before advancing the catheter too far relative to patient size.

No particular route or catheter type is exempt from this potentially fatal complication¹⁵. The actual position of the tip of the indwelling catheter should be confirmed by x-ray after insertion^{1,2,5,13,15,18}. Central venous catheters should be placed in the superior vena cava^{1,2,3,5,7,13,20} above its junction with the right atrium and parallel to the vessel wall^{9,20} and its distal tip positioned at a level above either the azygos vein or the carina of the trachea, whichever is better visualized.

Central venous catheters should not be placed in the right atrium unless specifically required for special relatively short term procedures, such as aspiration of air emboli during neurosurgery. Such procedures are nevertheless risk prone and should be closely monitored and controlled.

Indications for Use:

The multiple-lumen central catheter permits venous access to the central circulation.

Contraindications:

None known.

Central Venous Catheterization Warnings and Precautions:*

1. **Warning:** Do not place the catheter into or allow it to remain in the right atrium or right ventricle. Central vein catheters should be positioned so that the distal tip of the catheter is in the superior vena cava (SVC) above the junction of the SVC and the right atrium and lies parallel to the vessel wall. For femoral vein approach the catheter should be advanced into the vessel so that the catheter tip lies parallel to the vessel wall and does not enter the right atrium.
2. **Warning:** Practitioners must be aware of complications associated with central vein catheters including cardiac tamponade secondary to vessel wall, atrial or ventricular perforation, pleural and mediastinal injuries, air embolism, catheter embolism, thoracic duct laceration, bacteremia, septicemia, thrombosis, inadvertent arterial puncture, nerve damage, hematoma formation, hemorrhage, and dysrhythmias.
3. **Warning:** Do not apply excessive force in removing guide wire or catheters. If withdrawal cannot be easily accomplished, a chest x-ray should be obtained and further consultation requested.
4. **Warning:** The practitioner must be aware of potential air embolism problems associated with leaving open needles or catheters in central venous puncture sites or as a consequence of inadvertent disconnects. To lessen the risk of disconnects, only securely tightened Luer-Lock connections should be used with this device. Follow hospital protocol to guard against air embolism for all catheter maintenance.
5. **Warning:** Passage of the guide wire into the right heart can cause dysrhythmias, right bundle branch block⁶, and vessel wall, atrial or ventricular perforation.
6. **Warning:** Due to the risk of exposure to HIV (Human Immunodeficiency Virus) or other blood borne pathogens, health care workers should routinely use universal blood and body-fluid precautions in the care of all patients.
7. **Precaution:** Indwelling catheters should be routinely inspected for desired flow rate, security of dressing, correct catheter position and for secure Luer-Lock connection. Use centimeter markings to identify if the catheter position has changed.
8. **Precaution:** Only x-ray examination of the catheter placement can ensure that the catheter tip has not entered the heart or no longer lies parallel to the vessel wall. If catheter position has changed, immediately perform chest x-ray examination to confirm catheter tip position.
9. **Precaution:** For blood sampling, temporarily shut off remaining port(s) through which solutions are being infused.
10. **Precaution:** Alcohol and acetone can weaken the structure of polyurethane material. Therefore, care should be taken when instilling drugs containing alcohol or when using high concentration of alcohol or acetone when performing routine catheter care and maintenance. Alcohol should not be utilized to declog polyurethane catheters.
11. **Precaution:** Use of a syringe smaller than 10 ml to irrigate or declog an occluded catheter may cause intraluminal leakage or catheter rupture⁶.

Carefully read all warnings and precautions throughout procedure instructions.

Catheter Insertion Procedure: Use sterile technique.

1. **Precaution:** Place patient in slight Trendelenburg position as tolerated to reduce the risk of air embolism. If femoral approach is used, place patient in supine position.

2. Prep and drape puncture site as required.
3. Perform skin wheal with desired needle (25 Ga. or 22 Ga. needle). In kits where provided, a SharpsAway® disposal cup is used for the disposal of needles. Push needles into foam after use. Discard entire cup at completion of procedure. **Precaution: Do not reuse needles after they have been placed into the disposal cup. Particulate matter may adhere to needle tip.**
4. Prepare the catheter for insertion by flushing each lumen and clamping or attaching injection caps to the appropriate pigtails. Leave distal pigtail uncapped for guide wire passage. **Warning: Do not cut catheter to alter length.**
5. Insert introducer needle with attached Arrow Raulerson Syringe into vein and aspirate. (If larger introducer needle is used, vessel may be pre-located with 22 Ga. locator needle and syringe.) Remove locator needle.

Alternate Technique:

Catheter/needle may be used in the standard manner as alternative to introducer needle. If catheter/needle is used, Arrow Raulerson Syringe will function as a standard syringe, but will not pass spring-wire guide. If no free flow of venous blood is observed after needle is removed, attach syringe to the catheter and aspirate until good venous blood flow is established. **Precaution: The color of the blood aspirated is not always a reliable indicator of venous access¹⁰. Do not reinsert needle into introducer catheter.**

6. Because of the potential for inadvertent arterial placement, one of the following techniques should be utilized to verify venous access. Insert the fluid primed blunt tip transduction probe into the rear of the plunger and through the valves of Raulerson Syringe. Observe for central venous placement via a wave form obtained by a calibrated pressure transducer. Remove transduction probe (refer to Fig. 2).

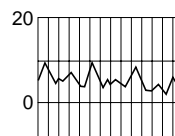


Fig. 2

Alternate Technique:

If hemodynamic monitoring equipment is not available to permit transducing a central venous wave form, check for pulsatile flow by either using the transduction probe to open the syringe valving system or by disconnecting the syringe from the needle. Pulsatile flow is usually an indicator or inadvertent arterial puncture.

7. Using the two-piece Arrow Advancer™, advance spring-wire guide through syringe into vein. **Warning: Aspiration with spring-wire guide in place will cause introduction of air into syringe. Precaution: To avoid leakage of blood from syringe cap do not reinfuse blood with spring-wire guide in place.**

Arrow Two-Piece Advancer™ Instructions:

- Using your thumb, straighten the “J” by retracting the spring-wire guide into the Advancer™ (refer to Fig. 3). When the tip is straightened, the spring-wire guide is ready for insertion.




Fig. 3

Introducing the Spring-Wire Guide:

- Place the tip of the Advancer™ – with “J” retracted – into the hole in the rear of the Raulerson Syringe plunger (refer to Fig. 4).



Fig. 4

- Advance spring-wire guide into the syringe approximately 10 cm until it passes through the valves.
- Lift your thumb and pull the Advancer™ approximately 4 cm to 8 cm away from the syringe. Lower thumb onto the Advancer™ and while maintaining a firm grip on the spring-wire guide, push the assembly into the syringe barrel to further advance the spring-wire guide. Continue until spring-wire guide reaches desired depth (refer to Fig. 5).

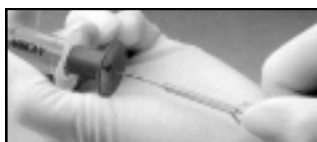

Fig. 5

Alternate Technique:

If a simple straightening tube is preferred, the straightening tube portion of the Advancer™ can be disconnected from the unit and used separately. Separate the Advancer™ tip or straightening tube from the blue Advancer™ unit. If the “J” tip portion of the spring-wire guide is used, prepare for insertion by sliding the plastic tube over the “J” to straighten. The spring-wire guide should then be advanced in the routine fashion to the desired depth.

8. Advancement of “J” tip may require a gentle rotating motion. **Warning: Do not cut spring-wire guide to alter length. Do not withdraw spring-wire guide against needle bevel to avoid possible severing or damaging of spring-wire guide.**
9. Hold spring-wire guide in place and remove introducer needle and Raulerson Syringe (or

catheter). **Precaution: Maintain firm grip on spring-wire guide at all times.** Adjust indwelling length of spring-wire guide according to desired depth of indwelling catheter placement.

10. Enlarge cutaneous puncture site with cutting edge of scalpel positioned away from the spring-wire guide. **Precaution: Do not cut guide wire.** Use vessel dilator to enlarge site as required. **Warning: Do not leave vessel dilator in place as an indwelling catheter to avoid possible vessel wall perforation.**
11. Thread tip of multiple-lumen catheter over spring-wire guide. Sufficient guide wire length must remain exposed at hub end of catheter to maintain a firm grip on guide wire. Grasping near skin, advance catheter into vein with slight twisting motion. **Precaution: Catheter clamp and fastener must not be attached to catheter until spring-wire guide is removed.**
12. Using cm marks on catheter as positioning reference points, advance catheter to final indwelling position.
13. Hold catheter at desired depth and remove spring-wire guide. The Arrow catheter included in this product has been designed to freely pass over the spring-wire guide. If resistance is encountered when attempting to remove the spring-wire guide after catheter placement, the spring-wire may be kinked about the tip of the catheter within the vessel (refer to Fig. 6). In this circumstance, pulling back on the spring-wire guide may result in undue force being applied resulting in spring-wire guide breakage. If resistance is encountered, withdraw the catheter relative to the spring-wire guide about 2-3 cm and attempt to remove the spring-wire guide. If resistance is again encountered remove the spring-wire guide and catheter simultaneously. **Warning: Although the incidence of spring-wire guide failure is extremely low, practitioner should be aware of the potential for breakage if undue force is applied to the wire.**

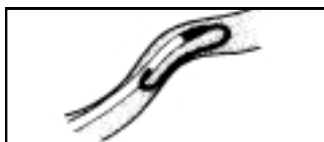

Fig. 6

14. Verify that the entire spring-wire guide is intact upon removal.
15. Check catheter lumen placement by attaching a syringe to each pigtail and aspirate until free flow of venous blood is observed. Connect all pigtails to appropriate Luer-Lock line(s) as required. Unused port(s) may be "locked" through injection cap(s) using standard hospital protocol. Slide clamps are provided on pigtails to occlude flow through each lumen during line and injection cap changes. **Precaution: To avoid damage to pigtails from excessive pressure, each clamp must be opened prior to infusing through that lumen.**
16. Secure and dress catheter temporarily.
17. Verify catheter tip position by chest x-ray immediately after placement. **Precaution: X-ray exam must show the catheter located in the right side of the mediastinum in the SVC with the distal end of the catheter parallel to the vena cava wall and its distal tip positioned at a level above either the azygos vein or the carina of the trachea, whichever is better visualized. If catheter tip is malpositioned, reposition and re-verify.**
18. Secure catheter to patient. Use triangular juncture hub with integral suture ring and side wings as primary suture site. In kits where provided, the catheter clamp and fastener should be utilized as a secondary suture site as necessary. **Precaution: Do not suture directly to the outside diameter of the catheter to avoid cutting or damaging the catheter or impeding catheter flow.**

Catheter Clamp and Fastener Instructions:

- After spring-wire guide has been removed and the necessary lines have been connect-

ed or locked, spread wings of rubber clamp and position on catheter as required to ensure proper tip location (refer to Fig. 7).

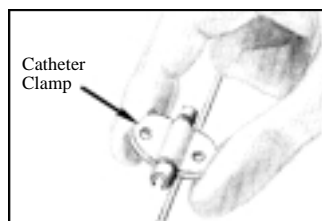


Fig. 7

- Snap rigid fastener onto catheter clamp (refer to Fig. 8).

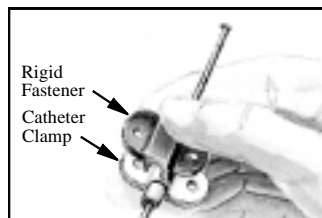


Fig. 8

- Secure catheter to patient by suturing the catheter clamp and fastener together to the skin, using side wings to prevent catheter migration (refer to Fig. 9).



Fig. 9

19. Dress puncture site per hospital protocol. **Precaution: Maintain the insertion site with regular meticulous redressing using aseptic technique.**
20. Record on the patient's chart the indwelling catheter length as to centimeter markings on catheter where it enters the skin. Frequent visual reassessment should be made to ensure that the catheter has not moved.

Catheter Exchange Procedure:

1. Use sterile technique
2. **Precaution: Prior to attempting a catheter exchange procedure, remove the catheter clamp and fastener.**
3. Proceed per hospital protocol. Cutting the catheter is not recommended due to the potential for catheter embolism.

Catheter Removal Procedure:

1. **Precaution: Place the patient in a supine position.**
2. Remove dressing. **Precaution: To avoid cutting of the catheter do not use scissors to remove the dressing.**
3. **Warning: Exposure of the central vein to atmospheric pressure may result in entry of air into the central venous system.** Remove suture(s) from catheter clamp and primary suture site. Be careful not to cut the catheter. Remove catheter slowly, pulling it parallel to the skin. As catheter exits the site, apply pressure with a dressing impermeable to air, e.g. vaseline gauze. Because the residual catheter track remains an air entry point until completely sealed, the occlusive dressing should remain in place for at least 24-72 hours dependent upon the amount of time the catheter was indwelling^{11,14,16,19}.
4. Upon removal of the catheter, inspect it to make sure that the entire length has been withdrawn.
5. Verify that the catheter was intact upon removal. Document removal procedure.

References:

1. Bar-Joseph G, Galvis AG. Perforation of the heart by central venous catheters in infants: guidelines to diagnosis and management. *J Pediatr Surg.* 1983;18:284-287.
2. Blitt CD, ed. *Monitoring in anesthesia and critical care medicine.* Central venous pressure monitoring. New York, NY: Churchill Livingstone, 1985.121-165.
3. Brandt RL, Foley WJ, Fink GH, Regan WJ. Mechanism of perforation of the heart with production of hydropericardium by a venous catheter and its prevention. *Am J Surg.* 1970;119:311-316.
4. Carbone K, Gimenez LF, Rogers WH, Watson AJ. Hemothorax due to vena caval erosion by a subclavian dual-lumen dialysis catheter. *South Med J.* 1987;80:795-796.
5. Collier PE, Ryan JJ, Diamond DL. Cardiac tamponade from central venous catheters – report of a case and review of the English literature. *Angiology.* September 1984;35:595-600.
6. Conn C. The importance of syringe size when using implanted vascular access devices. *J Vasc Access Nurs.* Winter 1993;3:11-18.
7. Curelaru J, Linder LE, Gustavsson B. Displacement of catheters inserted through internal jugular veins with neck flexion and extension. *Intens Care Med.* 1980;6:179-183.
8. Eissa NT, Kvetan V. Guide wire as a cause of complete heart block in patients with pre-existing left bundle branch block. *Anesthesiology.* 1990;73:772-774.
9. Iberti TJ, Katz LB, Reiner MA, Brownie T, Kwun KB. Hydrothorax as a late complication of central venous indwelling catheters. *Surgery.* November 1983;842-846.
10. Jobes DR, Schwartz AJ, Greenhow DE, Stephenson LW, Ellison N. Safer jugular vein cannulation: recognition of arterial punctures and preferential use of the external jugular route. *Anesthesiology.* 1983;59:353-355.
11. Kashuk JL, Penn I. Air embolism after central venous catheterization. *Surg Gynecol Obstet.* September 1984;159:249-252.
12. Kozeny GA, Bansal VK, Vertuno LL, Hano JE. Contralateral hemothorax secondary to chronic subclavian dialysis catheter. *Am J Nephrol.* 1984;4:312-314.

13. Maschke SP, Rogove HJ. Cardiac tamponade associated with a multi-lumen central venous catheter. *Crit Care Med.* 1984;12:611-612.
 14. Paskin DL, Hoffman WS, Tuddenham WJ. A new complication of subclavian vein catheterization. *Ann Surg.* March 1974;179:266-268.
 15. Peters JL, ed. *A Manual of Central Venous Catheterization and Parenteral Nutrition.* Boston, MA: John Wright PSG; 1983:58-61, 155-157.
 16. Phifer TJ, Bridges M, Conrad SA. The residual central venous catheter track – an occult source of lethal air embolism: case report. *J Trauma.* 1991;31:1558-1560.
 17. Sheep RE, Guiney WB Jr. Fatal cardiac tamponade. *JAMA.* 1982;248:1632-1635.
 18. Sigurdsson J, Riba P, Sigurdsson S. The wandering central venous catheter. *Intensive Care Med.* 1985;11:263-264.
 19. Thielen JB, Nyquist J. Subclavian catheter removal. *J Intravenous Nurs.* March/April 1991;14:114-118.
 20. Tocino IM, Watanabe A. Impending catheter perforation of superior vena cava: radiographic recognition. *Am J Roentgenology.* March 1986;146:487-490.
 21. Vaziri ND, Maksy M, Lewis M, Martin D, Edwards K. Massive mediastinal hematoma caused by a double-lumen subclavian catheter. *Artif Organs.* 1984;8:223-226.
 22. Wanscher M, Frifelt JJ, Smith-Sivertsen C, et al. Thrombosis caused by polyurethane double-lumen subclavian superior vena cava catheter and hemodialysis. *Crit Care Med.* 1988;16:624-628.
- Arrow International, Inc. recommends that the user be acquainted with the reference literature.
- *If you have any questions or would like additional reference information, please contact Arrow International, Inc.



K-17752-100B (9/96)

ARROW
INTERNATIONAL
3000 Bernville Road
Reading, PA 19605
1-800-523-8446
8 a.m. - 8 p.m. EST

